

Neuroclusal rehabilitation with planas direct tracks in the treatment of anterior crossbite – literature review

Luciano Aparecido de Almeida-Junior¹, Marcelo Muscas Polimeno², Ana Paula Tortelli³, Valéria Medau⁴

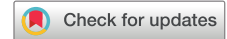¹Department of Clinics and Surgery, School of Dentistry, Federal University of Alfenas, Alfenas, Minas Gerais, Brazil

^{1,2,3,4}Marcelo Pedreira Institute, Alfenas, Brazil

¹Corresponding author

E-mail: ¹luciano.junior@unifal-mg.edu.br, ²mapolimeno@hotmail.com, ³anapaulatortelli@hotmail.com, ⁴valeriamedau@yahoo.com.br

Received 30 November 2023; accepted 26 January 2024; published online 21 February 2024
DOI <https://doi.org/10.21595/jfocg.2024.23837>



Copyright © 2024 Luciano Aparecido de Almeida Junior, et al. This is an open access article distributed under the Creative Commons Attribution License, which permits unrestricted use, distribution, and reproduction in any medium, provided the original work is properly cited.

Abstract. Planas direct tracks (PDTs) are an alternative treatment based on neuro occlusal rehabilitation (NOR) of various occlusal changes in the primary dentition and in the beginning of mixed dentition. Anterior crossbite is a very common malocclusion during this period. The aim of the present work was to report on Planas direct tracks through a literature review based on neuro-occlusal rehabilitation as a therapy for anterior crossbite (ACB). The search for articles was performed in the databases SciELO (Scientific Electronic Library Online), MEDLINE (National Library of Medicine-USA) and Google Scholar. After searching for articles, 12 studies were listed, however, after evaluating the inclusion and exclusion criteria, only 5 articles remained. The articles found proved to be effective in resolving cases with PDTs based on NOR. PDTs were more suitable for the treatment of anterior crossbite in the primary dentition. The inclination of the tracks was variable, both in the anterior and posterior regions, between 20° and 45° degrees. Three case reports in primary dentition observed ACB correction after 30 days with PDT. As a result, two case reports reported that the treatment of ACB was resolved after 45 days with the effects of clockwise rotation of the mandible and its repositioning. Another effect observed was the uncrossing of the anterior teeth, presenting an uncrossing of the bite and improvements in facial and postural symmetry. The NOR-based PDT for the case reports presented promoted the resolution of ACB malocclusion, promoting the correction of jaw posture, and in turn, improving the facial and postural symmetry of the mandible.

Keywords: functional jaw orthopedics, anterior crossbite, planas direct tracks, mesiocclusion.

1. Introduction

Neuro occlusal rehabilitation (NOR) defined by Pedro Planas is an effective and very efficient treatment solution for functional crossbites. The objective of this treatment is to eliminate deviations and interferences that contribute to morphological and functional changes in the stomatognathic system [1, 2]. The PDT technique, which was developed by Pedro Planas in the 1970s, is widely used in treatments based on NOR to correct dental or functional changes in the deciduous dentition and the beginning of mixed dentition, regaining normal occlusion, jaw posture, position of the condyle and masticatory function [1, 3].

Initially, it was recommended for unilateral posterior crossbite [1, 3]. This therapy consists of selective grinding and, if necessary, the incorporation of light cured resin in the occlusal area of the posterior deciduous teeth or in the incisal layer of the anterior teeth to establish planes and correctly position the mandible, stimulating the physiological development of the stomatognathic system [4].

Crossbite is a very common malocclusion in primary dentition due to poor oral habits or genetic changes [3, 5]. ACB is characterized by an abnormal anteroposterior relationship between

the maxilla and mandible in maximum habitual intercuspation [6, 7]. Some strategies are important for the treatment of ACB due to the great paradigm that exists between the difficulty of treatment and relapses [8]. A therapeutic resource found for the correct treatment of ACB in Functional Jaw Orthopedics is PDT [8]. Therefore, the objective of the present work was to report on PDT through a literature review based on NOR as a therapy for ACB.

2. Methods

The search for articles was performed in the Health Sciences databases SciELO (Scientific Electronic LibraryOnline), MEDLINE (National Library of Medicine-USA) and Google Scholar. An integrative literature review was carried out and after reading the abstracts, articles were selected according to the previously established inclusion and exclusion criteria. The descriptors were in English and Portuguese, being: “Ortopedia Funcional dos Maxilares” e “Tratamento para Classe III” e “Pistas Diretas Planas”, “Ortopedia Funcional dos Maxilares” e “Tratamento para Mesioclusão” e “Pistas Diretas Planas”, “Mordida Cruzada Anterior” e “Pistas Diretas Planas”, “Anterior Crossbite” AND “Planas Direct Tracks”, “Functional Jaw Orthopedics” AND “Mesioclusion” AND “Planas Direct Tracks.”

The inclusion criteria were articles from national and international magazines, treatment with PDT, mesiocclusion (Class III) with ACB, English, French, Spanish and Portuguese languages from the period of 2012 to 2023. The exclusion criteria were theses, dissertations, monographs, technical reports, reference works and articles that, after reading the abstracts, did not converge with the proposed study objective, in addition to publications that are repeated in the databases and virtual library. After searching for articles, 12 initial studies were listed, however, after reading the titles and abstracts, 3 articles were excluded that were considered dissections or scientific reports. After reading the articles in full, 5 articles met the inclusion and exclusion criteria.

3. Results

Rossi et al. [10] presented a case report of a patient aged 4 years and 2 months with functional ACB, mesofacial pattern, primary dentition, absence of caries or periodontal lesions and good hygiene conditions. After manipulating the mandible in centric relation, they concluded that it was functional ACB due to premature contacts between the upper and lower incisors. Orthopedic therapy based on Pedro Planas PDT was proposed in the anterior region. After occlusal adjustment, PDT were made in composite resin at a 45° angle on the upper incisors. The PDTs were maintained even after the uncrossing of the incisors and the visits were bimonthly for adjustments of the PDT and selective wear in order to avoid limiting and/or hindering the mandibular movements. The treatment followed the dental changes. Correction of the ACB and stabilization of the posterior region occurred after 30 days.

A clinical case by Vora; Misal; Tonishal [11], with a 4-year-old patient with a concave profile, ACB and mesial pitch no greater than 3 mm and a horizontal growth pattern. After mandibular manipulation in centric relation, the patient presented with an overbite. The treatment was PDT using the indirect method made from the size of the width of the second molars with inclination for the mesiocclusion treatment. The follow-up period was 6 months. The study observed a negative overjet, a slight decrease in overbite and a decrease in the linear distance of the mesial step. PDT caused clockwise rotation of the mandible and its retropositioning, uncrossing the anterior teeth.

A case report by Devasya et al. [2] with a 5-year-old patient diagnosed with ACB and concave profile was presented. PDT with inclination for mesiocclusion in the first and second primary molars was proposed for the treatment of ACB. There was a modification in the technique with the production using the indirect technique in self-polymerizing acrylic resin with the inclination of the tracks at angles of 20° to 45° at the top and bottom. After 30 days, there was initial correction of the ACB and after 2 months, there was stabilization of the occlusion.

Zózimo et al. [12] reported the case of a patient aged 5 years and 3 months, diagnosed with functional ACB (pseudoclass III). The main complaint was aesthetics. The treatment plan was PDT with an inclination towards the treatment of mesiocclusion with an execution time of 1 hour and monthly returns to monitor the case. The authors concluded that PDT promoted the correction of functional ACB within 30 days of treatment. Furthermore, this technique can be used to treat ACB early. Its advantages in relation to other treatments found in the literature are due to the quick preparation and lower cost of the technique.

The case report by Bezerra et al. [13] presented a 7-year-old male patient diagnosed with right unilateral ACB and unfavorable behavior. The treatment was selective grinding on teeth 53 and 83, and subsequently, the creation of PDT based on NOR. The mandible was uncrossed immediately after PDT installation and after 3 months, the occlusion was stabilized. PDT is an alternative for these cases since it provides immediate uncrossing of the patient's bite, enabling occlusal stability. The technique used can treat ACB early. It is quick to perform and less expensive.

4. Discussion

Functional Jaw Orthopedics, in short, is a specialty of dentistry that promotes the adjustment of occlusion and reestablishes the function of the stomatognathic system and the patient's aesthetics [7]. The present study showed that therapeutic resources based on NOR promoted a satisfactory correction in the patient's occlusion, function and aesthetics. PDTs are an alternative for treatments of mesiocclusion and functional ACB or pseudoclass III [1-13], with the advantages of being quick to create [12, 13], less expensive for the patient [12] and with favorable results for non-cooperative patients [13].

According to Rossi et al. [10] and Zózimo et al. [12], PDT therapy showed an improvement in occlusion 30 days after installation. Since each patient had some type of response, Garbin et al. [14] managed to restore normal occlusion after only 45 days with PDT. Vora, Misal and Tonishal [11] also opted to use PDT in patients aged 4 years, with this therapy being an indication for primary dentition [3,7]. Braga et al. [15] used the association of an encapsulated appliance with an expander, creating a unilateral constructive bite with a Gomes flap due to a posterior crossbite, a modified progenic appliance and stabilized the Klammt appliance after complete correction of the functional anterior crossbite. In the case report of skeletal Class III, Esperancinha and Póvoas [16] used the Planas Indirect Tracks device for Class III. Even with the differences in malocclusion and therapies that OFM employs, the resolution of cases and the return of the patient's aesthetics and function occurs satisfactorily [1, 2, 4, 6, 10-16].

Matos et al. [5] observed that an inclination of the PDT at 30° is adequate for the treatment of ACB. On the other hand, Rossi et al. [10], in their clinical case, presented an angulation of 45° and obtained correction of the ACB. Devasya et al. [2] used angulations of 20° to 45° in the posterior region to treat the ACB. The limitations of the study included the difficulty of finding studies with strong scientific results so that we could draw a more comprehensive conclusion. All studies were clinical cases and would require randomized clinical studies and systematic reviews with meta-analysis on the topic. Hence, the importance of a literature review study in which we can see the missing gaps and observe what knowledge is available in the area is emphasized.

5. Conclusions

The current literature based on the articles found reports that NOR-based PDT is an alternative for the treatment of ACB. Both direct and indirect construction techniques, with or without modification, corrected the malocclusion in a variable period of time according to the patient's biological response. The great advantages of this technique are that it does not depend on the patient's cooperation, is quick to perform and is low cost. However, the studies found were case reports which are weaker scientific evidence. In turn, the present study suggests that further

research such as randomized clinical trials, systematic reviews and meta-analyses are necessary.

Acknowledgements

The authors have not disclosed any funding.

Data availability

The datasets generated during and/or analyzed during the current study are available from the corresponding author on reasonable request.

Author contributions

Luciano Aparecido de Almeida-Junior: conceptualization; data curation; investigation; methodology; literature review; writing – original draft preparation; writing – review and editing. Marcelo Muscas Polimeno: investigation; writing – original draft preparation; writing – review and editing. Ana Paula Tortelli: writing – original draft preparation; writing – review and editing. Valéria Medau: supervision; writing – original draft preparation; writing – review and editing.

Conflict of interest

The authors declare that they have no conflict of interest.

References

- [1] J. I. Garbin, B. Wakayama, R. R. Santos, T. A. S. Roviada, and C. A. S. Garbin, “Pistas directas planas para el tratamiento de la mordida cruzada posterior,” *Revista Cubana de Estomatología*, Vol. 51, No. 1, pp. 113–120, 2014.
- [2] A. Devasya, N. K. Ramagoni, M. Taranath, K. E. Prasad, and M. Sarpangala, “Acrylic planas direct tracks for anterior crossbite correction in primary dentition,” *International Journal of Clinical Pediatric Dentistry*, Vol. 10, No. 4, pp. 399–403, Jan. 2017, <https://doi.org/10.5005/jp-journals-10005-1473>
- [3] P. C. Planas, *Reabilitação Neuroclusal*. Rio de Janeiro: Medisi, 1997.
- [4] M. R. C. Brandão, *Pista Direta Planas como recurso terapêutico em diversos tipos de maloclusões. Nova Visão em Ortodontia e Ortopedia Funcional dos maxilares*. São Paulo: Editora Santos, 2004.
- [5] G. R. Matos, R. R. Neto, A. J. M. Júnior, and R. B. B. Junior, “Influence of the inclination of the incisal edge of planas direct tracks on deciduous dentition with anterior crossbite: finite-elements study,” *European Journal of Dentistry*, Vol. 16, No. 3, pp. 528–535, Nov. 2021, <https://doi.org/10.1055/s-0041-1735435>
- [6] R. R. D. Santos, A. J. Ispere Garbin, and C. A. Saliba Garbin, “Early correction of malocclusion using planas direct tracks,” *Case Reports in Dentistry*, Vol. 2013, pp. 1–4, Jan. 2013, <https://doi.org/10.1155/2013/395784>
- [7] W. A. Simões, *Ortopedia funcional dos maxilares: através da reabilitação neuro-oclusal*. Porto Alegre: Artes Médicas, 2003.
- [8] R. Kanas, L. Carapezza, and S. Kanas, “Treatment classification of class III malocclusion,” *Journal of Clinical Pediatric Dentistry*, Vol. 33, No. 2, pp. 175–186, Dec. 2008, <https://doi.org/10.17796/jcpd.33.2.431877341u182416>
- [9] German Ramirez-Yañez, “Treatment of anterior crossbite in the primary dentition with esthetic crowns: report of 3 cases,” *Pediatric Dentistry*, Vol. 33, No. 4, pp. 339–342, 2011.
- [10] L. B. Rossi, K. E. D. C. Pizzol, E. M. Boeck, N. Lunardi, and A. J. I. Garbin, “Correção de mordida cruzada anterior funcional com a terapia de pistas diretas planas: relato de caso,” *Revista da Faculdade de Odontologia de Lins*, Vol. 22, No. 2, pp. 45–50, Dec. 2012, <https://doi.org/10.15600/2238-1236/fo1.v22n2p45-50>
- [11] K. Vora, A. Misal, and N. Toshniwal, “An innovative approach for correction of pseudo class III malocclusion with the use of “Planas direct tracks”,” *APOS Trends in Orthodontics*, Vol. 3, No. 6, p. 190, Jan. 2013, <https://doi.org/10.4103/2321-1407.121440>


- [12] T. I. L. Zózimo, G. R. P. Santos, J. V. B. S. Silva, G. S. G. Silva, and S. M. S. Silva, “Correção de mordida cruzada anterior funcional com pistas diretas planas: relato de caso clínico,” *Archives Health Investigation*, Vol. 7, No. 5, p. 72, 2018.
- [13] K. R. Bezerra, L. A. Souza, M. Cordeiro, F. Bontorin, and A. L. Fatturi, “Tratamento de mordida cruzada anterior com o uso de pista planas direta: uma alternativa para pacientes com dificuldades comportamentais – relato de caso,” *Revista Gestão e Saúde*, Vol. 1, No. 24, pp. 10–21, Jan. 2022, <https://doi.org/10.17648/1984-8153-rgs-v1n24-10>
- [14] A. J. I. Garbin, B. Wakayama, J. A. Batista, and T. A. Saliba, “Neuroclusal rehabilitation and Planas direct tracks in the treatment of functional crossbite in children: case report,” *Revista Sul-Brasileira de Odontologia*, 2021.
- [15] C. S. Braga, R. P. Morais, L. C. S. Franzin, and R. C. G. Oliveira, “Integrated treatment orthodontic and pediatric dentistry,” *Revista UNINGÁ Review*, Vol. 24, No. 3, pp. 20–26, 2015.
- [16] C. P. L. Esperancinha and C. P. Póvoas, “Abordagem multidisciplinar da disfunção temporomandibular – opção terapêutica através de aparelhos ortopédicos funcionais,” *Revista Portuguesa de Estomatologia, Medicina Dentária e Cirurgia Maxilofacial*, Vol. 55, No. 1, p. e56, Oct. 2014, <https://doi.org/10.1016/j.rpemd.2014.11.017>



Luciano Aparecido de Almeida-Junior has a D.D.S. and an M.Sc, and a Ph.D. He is a full-time Professor of Orthodontics at the School of Dentistry of Alfenas at the Federal University of Alfenas. He is a specialist in orthodontics and functional jaw orthopedics. He works in research with cell cultures, pulp stem cells, and the inflammatory response in bone.



Marcelo Muscas Polimeno has a D.D.S. He is a specialist in functional jaw orthopedics. Former president of the Brazilian Academy of Functional Jaw Orthopedics.



Ana Paula Tortelli has a D.D.S. She is a specialist and Professor in functional jaw orthopedics.



Valéria Medau has a D.D.S. and an M.Sc. She is a specialist and professor in orthodontics and functional jaw orthopedics. Current president of the Brazilian Academy of Functional Jaw Orthopedics.